Original Article

Quantitative Analysis and Comparison of Mast Cells in Breast Carcinomas and Axillary Lymph Nodes

Sritanu Jana, Sulekha Ghosh, Arindam De[1], Subrata Pal[2], Sanjay Sengupta, Tapan Ghosh

Departments of Pathology and [1]Community Medicine, B S Medical College, Bankura, [2]Department of Pathology, College of Medicine and Sagore Dutta Hospital, Kolkata, West Bengal, India

Abstract

Introduction: The incidence of breast cancer is increasing throughout the world and it has become the major health problem. Many risk factors and prognostic factors of breast cancer have been identified. Inflammatory cells in the tumor stroma have gained increasing interest on recent time. **Aims and Objectives:** The study was undertaken to identify the prognostic impact of presence of stromal mast cells in breast carcinomas. **Materials and Methods:** It was an institution-based descriptive study with cross-sectional design. Total 44 specimens of postoperative breast tissue and dissected axillary lymph nodes of carcinoma breast were taken as sample. After processing of tissue, the slide was stained with hematoxylin and eosin stain and subsequently with toluidine blue stain. Counting of mast cells was done in toluidine blue stain. **Results and Analysis:** Among 44 cases, the mean age of patients was 45.32 years and infiltrating ductal carcinoma-no special type was the most common type. According to histological grading, Grade III was most common. The mean mast cell count in breast lump was 5.76/high-power field (HPF). The mean mast cell count in axillary lymph node was 11.20/HPF among 27 cases. It was observed that when the tumor grade increases, the number of must cell decreased per HPF. **Conclusion:** This study indicated that the number of mast cells in breast cancer was inversely correlated with the grade of this tumor.

Keywords: *Axillary lymph node, breast carcinoma, mast cell, metastasis, prognosis*

Introduction

Breast carcinoma is the most common malignant tumor and the leading cause of carcinoma-related death in women, with an annual incidence of >1000000 cases worldwide.[1] The incidence of breast cancer is increasing throughout the world, and it has become the major health problem. The incidence of breast cancer in India is 9–28.6/100000 women.[2] Carcinoma is the most common malignancy in the breast, and the breast cancer is most common nonskin malignancy in women.[3] In recent years, interest in prognostic factors has been stimulated by the success of systemic adjuvant therapy for early stage of cancer of the breast.[4] Different prognostic factors are patient's age, BRCA 1 status, pregnancy, early diagnosis, presence or absence of invasion, size of tumor, axillary lymph node status, anatomical quadrant, cytoarchitectural type, microscopic grade, hormone receptor status, margin status, tumor necrosis, stromal reaction, microvessel density, elastosis, and pattern of lymph node reaction.[5] The prognostic significance of amount of stromal connective tissue is controversial. Inflammatory cells in tumor stroma have gained increasing interest because it was previously believed that the stromal cells were the result of host response against the cancer cell, but it may also contribute to the development of malignancy. Thus, the study aimed to find the frequency and prognostic impact of stromal mast cells.[6-9] Eosinophils and mast cells are the inflammatory cells found in the stroma of malignant tissue. Mast cells are derived from the specific bone marrow progenitor cells and migrate to the tissue where they mature depending on the microenvironmental condition. These cells have granules containing heparin and histamine. Toluidine blue is one of the important metachromatic stains which stain the granules of the mast cells. Metachromasia depends both on the dye and tissue components that unite with the dye to exhibit metachromasia. All metachromatic dyes are cationic, and their peculiar tinctorial properties almost certainly depend on their tendency to polymerize. Heparin in mast cell granules is an acid polysaccharide, which permits the polymerization of

How to cite this article: Jana S, Ghosh S, De A, Pal S, Sengupta S, Ghosh T. Quantitative analysis and comparison of mast cells in breast carcinomas and axillary lymph nodes. Clin Cancer Investig J 2017;6:214-8.

Address for correspondence:
Dr. Subrata Pal, Kalpataru Apartment, Sahid Colony, BT Road, PS - Khardaha, North 24 Pargana, West Bengal, India.
E-mail: subratapal1985@gmail.com

Access this article online

Website: www.ccij-online.org

DOI: 10.4103/ccij.ccij_52_17

Quick Response Code:

basic dye molecule in toluidine blue. Mast cells could facilitate the tumor angiogenesis through heparin-like molecule, and heparin could permit neovascularization and metastasis through anticlotting effect.[10] Moreover, mast cells secrete histamine and growth factors, such as vascular endothelial growth factor, platelet-derived growth factor, stem cell factor, and nerve growth factor. These cells are rich in metalloprotease which are necessary for tumor invasiveness.[11] On the other hand, mast cells can also be detrimental to tumor growth by secreting several cytokines and proteolytic enzymes and participating in apoptosis of the malignant cell, such as interleukin-4.[12] The impact of mast cells on the prognosis of malignant breast tumors is still controversial. Few studies in stromal mast cell in the invasive breast carcinoma have been done and those studies indicated that the increased stromal mast cells were correlated with favorable prognosis.[13-15] In some studies, mast cell count was found to be correlated with the positivity of estrogen and progesterone receptor. Thus, the dual role of mast cell in inhibiting or promoting tumor growth needs further investigations.[16] In this background, the aim of the study was followings.

1. To estimate the number of mast cells in malignant tumor and enlarged axillary lymph nodes
2. To find any correlation between the number of mast cells, tumor grading, and lymph node metastasis.

Materials and Methods

The study was conducted in pathology department in collaboration with the department of surgery at our institute from February 2014 to January 2015. It was a descriptive study with cross-sectional design. The study was conducted after receiving approval from the Institutional Ethics Committee. Study population were adult female having history of breast lump with or without enlarged axillary lymph nodes. Sample size was complete enumeration of patients attending hospital during study period. Total 44 specimens of postoperative breast tissue and enlarged axillary lymph nodes of suspected breast malignancy were available for histopathological examination.

Sample was collected from the specimens sent for histological examination in the pathology department. Axillary tissues were separated from the breast if attached to it. External appearance was noted and the specimen was palpated for any mass or nodularity. Sections from representative areas were taken. Tissue processing, section cutting, and staining were done as per standard histopathology process. Diagnosis and classification of the lesions to be done by hematoxylin and eosin stain (H and E). Microscopic grading of malignant breast lesions was done according to Nottingham modifi cation of Bloom-Richardson System in H and E-stained slides, under light microscope. Counting of mast cells was done in toluidine blue-stained slides [Figures 1 and 2]. Mast cell number in six high-power fields (HPF) was counted and the average was taken. Data analysis was done with the help of IBM Statistical Package for the Social Sciences (SPSS) Software 20.0 version.

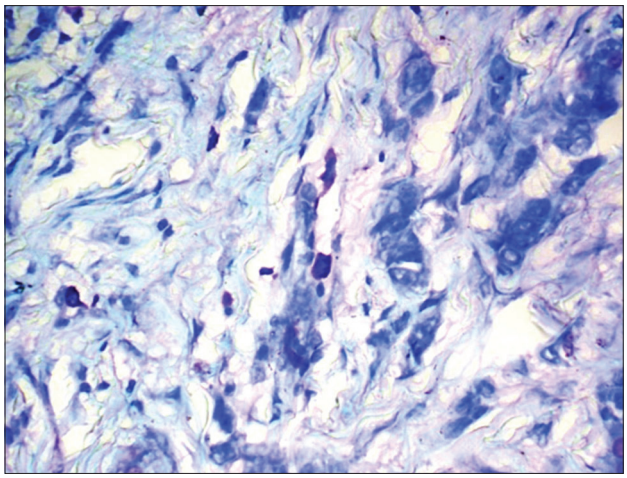

Figure 1: Infiltrating ductal carcinoma mast cells in peritumoral tissue (toluidine blue stain, ×400 view)

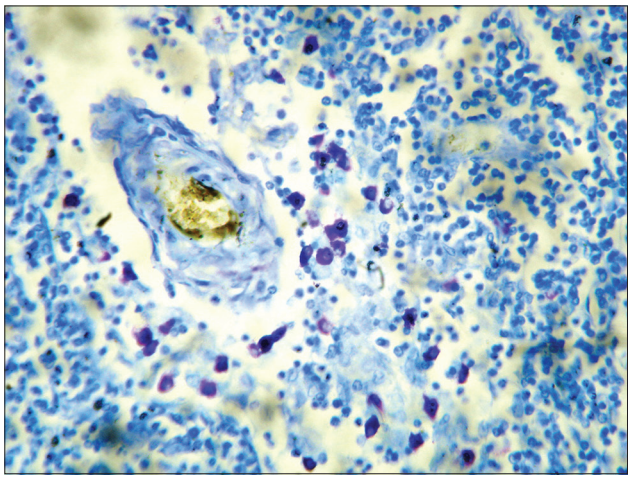

Figure 2: Mast cell in a reactive lymph node in a case of ductal carcinoma breast (toluidine blue stain, ×400 view)

Result and Analysis

Among 44 patients, mean age was 45.32 years and age range was between 18 and 75 years. On clinical examination, it was found that overlying skin was fixed in 65.9% and nipple retraction was found in 63.6%. Lymph nodes were palpable in 61.4% of cases and lump size >5 cm in 52.3% of cases [Table 1].

Histological types of the cases in our study were infiltrating ductal carcinoma-no special type (IDC-NST) 77.3%, mucinous carcinoma 11.4%, medullary carcinoma 4.4%, invasive lobular carcinoma 2.3%, metaplastic carcinoma 2.3%, and papillary carcinoma 2.3%. According to histological grading, Grade I accounted 6.8% of the cases, Grade II tumors were 38.6%, and Grade III tumor were diagnosed in 54.6 of the cases [Table 2].

Among 27 palpable lymph nodes, 70.37% were metastatic and 29.63% were reactive. In reactive lymph nodes, five

Table 1: Distribution of study population according to some variable of breast lump (*n*=44)

Variables	Frequency (%)
Overlying skin	
Fixed	29 (65.9)
Free	15 (34.1)
Nipple	
Retracted	28 (63.6)
Not retracted	16 (33.4)
Lymph node	
Palpable	27 (61.4)
Not palpable	17 (38.6)
Size of breast lump (cm)	
<2	3 (6.8)
2-5	18 (40.9)
>5	23 (52.3)

Table 2: Distribution of study population according to histological type, staging, and grading of breast lump (*n*=44)

Variables	Frequency (%)
Histological type	
IDC-NST	34 (77.3)
Mucinous carcinoma	5 (11.4)
Medullary carcinoma	2 (4.4)
Lobular carcinoma	1 (2.3)
Metaplastic carcinoma	1 (2.3)
Papillary carcinoma	1 (2.3)
Histological grade	
Grade I	3 (6.8)
Grade II	17 (38.6)
Grade III	24 (54.6)

IDC-NST: Infiltrating ductal carcinoma-no special type

patients had follicular hyperplasia and three patients had sinus histiocytosis. The mean mast cell count in breast lump was 5.76/HPF (standard deviation [SD] 3.51) and median 5.25/HPF. Total 27 clinically palpable lymph nodes were present, and the mean mast cell count in lymph node was 11.20/HPF (SD 12.07). The mean mast cell count in breast lump in Grade I was 13.03/HPF (SD 4.5), Grade II 6.3/HPF (SD 3.5), and Grade III 4.47/HPF (SD 1.9). One-way ANOVA shows that there was significant difference between three groups. When the tumor grade was increasing, the number of mast cells was decreasing per HPF, but there was no significant association between tumor grade and mean mast cell count/HPF in lymph node. The median value of mast cell count in breast lump in case of palpable lymph node was 5.00/hpf and nonpalpable lymph node was 5.40/HPF. Mann–Whitney U-test did not found any significant association between these two groups. The median value of mast cell count in breast lump with metastasis was 4.5/HPF, and in case of reactive lymph nodes, it was 5.5/HPF. Mann–Whitney U-test did not shown any significant association between these two groups. The median value of mast cell count in lymph node with metastasis was 5.1/hpf, and in case of reactive lymph nodes, it was 19.15/hpf. Mann–Whitney U-test found significant association between these two groups. Histological types for good prognosis were IDC-NST, mucinous carcinoma, lobular carcinoma, and papillary carcinoma; medullary carcinoma and metastatic carcinoma had poor prognosis. The mean of mast cell count in breast lump in case of bad prognosis type (4.06/HPF) was less than the mean of good prognosis type (6.03/HPF), and this difference was statistically significant. The mean of mast cell in lymph node in case of bad prognosis type (3.98/HPF) was less than the mean of good prognosis type (7.33/HPF), and this difference was not significant statistically. Overlying skin fixed in 65.9%, nipple retracted in 63.6%, palpable lymph node in 61.4% of cases, and lump size >5 cm in 52.3% of cases.

Discussion

Identification of new prognostic markers for patients with breast cancers is an important issue since the current treatment guidelines recommend adjuvant treatment for about 90% of the patients with node-negative disease. About 30% of the patients actually will benefit from the therapy. Thus, it is important to identify new markers for this subgroup of patients who might not need adjuvant chemotherapy. Few previous studies indicated that increased stromal mast cells are correlated to a favorable prognosis of breast carcinoma.[17]

In the present study, age of the patients was distributed between 18 and 75 years. The mean age in our study was 45.32 years, which was similar to previous study of Siddiqui *et al*. (48 years) and Saxena *et al*.[18,19] Among the histological types, IDC-NST was most frequent type and followed by mucinous, medullary, and lobular carcinoma in the present study. The finding was slightly different from Robbins where maximum cases were IDC-NST, lobular, and then others.[20] Saxena *et al*. found 88.2% IDC in their study population, and the second common malignancy was lobular carcinoma (3.7%).[19]

In this study, the mean mast cell count in breast lump in Grade I was highest than Grade II and Grade III. When the tumor grade was increasing, the number of must cell decreasing per HPF. Bowers *et al*. described that a higher number of mast cells were found in the noninvolved axillary lymph nodes in those women with a better prognosis.[21] Mitra *et al*. conducted a study on 108 cases with invasive breast cancer, where grading was done according to the Nottingham modification of the Bloom-Richardson system. Fifty-four (50%) women had Grade 1, 16 (14.8%) had Grade 2, and 38 (35.2%) had Grade 3 tumor. The presence of stromal mast cells correlated significantly to low-grade tumors.[22]

The median value of mast cell count in lymph node with metastasis was lower than reactive lymph nodes in this

study.[22] In the present study, more mast cells were found in the noninvolved axillary lymph node than the metastatic nodes, similar to the findings of Naik *et al*.,[21] Horny *et al*.,[23] and Naik *et al*.[24]

Samoszuk *et al*. counted mast cells in peritumoral fibrous tissue and found that mast cells were restricted to peritumoral fibrous tissue. Mast cell heparin is a powerful inhibitor of clonogenic growth of tumor cells cultured with fibroblast.[25] della Rovere *et al.* has done a study where they counted mast cells in peritumoral area.[26] In this study, it was found that mast cells were more in number in those slides where overlying nipple and areola were present. It was due to normally higher number of mast cells in normal skin and large duct epithelium. During counting of mast cells, skin and large duct epithelium should be excluded from the study.

In this study, histological types for good prognosis (IDC-NST, mucinous carcinoma, lobular carcinoma, and papillary carcinoma) had lower mean must cell count than poor prognosis types (medullary carcinoma and metastatic carcinoma).

Mast cells accumulate around tumors and can either promote or inhibit tumor growth depending on the local stromal conditions. The presence of stromal mast cells in other malignant tumors has been of interest.

Thus, it was concluded that the absence of metastasis in the lymph node was a good prognostic indicator in breast cancer and mast cell count is significantly higher in reactive lymph node so mast cell count can be an independent prognostic factor. When the tumor grade was increasing, the number of mast cell was decreasing per HPF, but there was no significant association between tumor grade and mean mast cell count/HPF in lymph node. Mast cell in breast lump in case of bad prognosis type was significantly lesser than mean of good prognosis type.

Conclusion

It can be said that higher mast cell count is well related with good prognosis of breast cancers, and in rural setup where immune staining is not available, the mast cell count by to toludine blue stain can be used as a screening procedure to determine the prognosis of breast cancers and their sensitivity to hormonal therapy.

Financial support and sponsorship

Nil.

Conflicts of interest

There are no conflicts of interest.

References

1. Parkin DM, Bray F, Ferlay J, Pisani P. Estimating the world cancer burden: Globocan 2000. Int J Cancer 2001;94:153-6.
2. National Cancer Registry Programme. Consolidated Report of the Population Based Cancer Registries 1990–96. New Delhi: ICMR; 2001.
3. Kumar V, Abbas AK, Fausto N, editors. Robbins and Cortan: Pathologic Basis of Disease. 7th ed. Philadelphia, PA: Elsevier Saunders; 2004. p. 1129.
4. Rosai J. Rosai and Ackerman's Surgical Pathology. 9th ed., Vol. 2. Edinburgh, New York: Mosby; 2004. p. 1788.
5. Rosai J. Rosai and Ackerman's Surgical Pathology. 9th ed., Vol. 2. Edinburgh, New York: Mosby; 2004. p. 1825.
6. Balkwill F, Mantovani A. Inflammation and cancer: Back to Virchow? Lancet 2001;357:539-45.
7. Coussens LM, Werb Z. Inflammatory cells and cancer: Think different! J Exp Med 2001;193:F23-6.
8. Almholt K, Johnsen M. Stromal cell involvement in cancer. Recent Results Cancer Res 2003;162:31-42.
9. de Visser KE, Eichten A, Coussens LM. Paradoxical roles of the immune system during cancer development. Nat Rev Cancer 2006;6:24-37.
10. Gooch JL, Lee AV, Yee D. Interleukin 4 inhibits growth and induces apoptosis in human breast cancer cells. Cancer Res 1998;58:4199-205.
11. Aaltomaa S, Lipponen P, Papinaho S, Kosma VM. Mast cells in breast cancer. Anticancer Res 1993;13:785-8.
12. Dabiri S, Huntsman D, Makretsov N, Cheang M, Gilks B, Bajdik C, *et al.* The presence of stromal mast cells identifies a subset of invasive breast cancers with a favorable prognosis. Mod Pathol 2004;17:690-5.
13. Rajput AB, Turbin DA, Cheang MC, Voduc DK, Leung S, Gelmon KA, *et al.* Stromal mast cells in invasive breast cancer are a marker of favourable prognosis: A study of 4,444 cases. Breast Cancer Res Treat 2008;107:249-57.
14. Theoharides TC, Conti P. Mast cells: The Jekyll and hyde of tumor growth. Trends Immunol 2004;25:235-41.
15. Alderson MR, Hamlin I, Staunton MD. The relative significance of prognostic factors in breast carcinoma. Br J Cancer 1971;25:646-56.
16. Hutter RV. The influence of pathologic factors on breast cancer management. Cancer 1980;46:961-76.
17. Berg JW, Robbins GF. Factors influencing short and long term survival of breast cancer patients. Surg Gynecol Obstet 1966;122:1311-6.
18. Siddiqui MS, Kayani N, Sulaiman S, Hussainy AS, Shah SH, Muzaffar S, *et al.* Breast carcinoma in Pakistani females: A morphological study of 572 breast specimens. J Pak Med Assoc 2000;50:174-7.
19. Saxena S, Rekhi B, Bansal A, Bagga A, Chintamani, Murthy NS, *et al.* Clinico-morphological patterns of breast cancer including family history in a New Delhi hospital, India – A cross-sectional study. World J Surg Oncol 2005;3:67.
20. Lester SC. The breast. In: Kumar V, Abbas AK, Fausto N, editors. Robbins and Cortan Pathologic Basis of Disease. 7th ed. Philadelphia, PA: Elsevier Sounders; 2004.
21. Naik R, Pai MR. Mast cell numbers in lymphnode lesions. Indian J Pathol Microbiol 1998;41:153-6.
22. Mitra H, Mohammad AR, Parvin R, Farkhani HS. Mast cells in invasive ductal breast carcinoma. J Res Med Sci 2008;13:255-9.
23. Horny HP, Horst HA. Frequency distribution of tissue mast cells and eosinophilic granulocytes in tumor-draining axillary and paracolic lymph nodes. J Cancer Res Clin Oncol 1986;112:151-5.
24. Naik R, Baliga P, Bansal R, Pai M. Distribution of mast cells in the axillary lymph nodes of breast cancer patients. J Indian Med Assoc 1997;95:606-7.

25. Samoszuk M, Kanakubo E, Chan JK. Degranulating mast cells in fibrotic regions of human tumors and evidence that mast cell heparin interferes with the growth of tumor cells through a mechanism involving fibroblasts. BMC Cancer 2005;5:121.
26. della Rovere F, Granata A, Familiari D, D'Arrigo G, Mondello B, Basile G, *et al*. Mast cells in invasive ductal breast cancer: Different behavior in high and minimum hormone-receptive cancers. Anticancer Res 2007;27:2465-71.