

Assessment and comparison of the radiographic distance of mandibular first and second molars' apexes from the inferior alveolar nerve canal on panoramic and CBCT views

Abstract

Background. Due to its vulnerability to injury during procedures involving the mandible, such as dental implant surgery and molar extraction, the inferior alveolar nerve canal of the mandible is clinically very significant. This necessitates anatomical investigations based on imaging technologies. The radiographic distance between the inferior alveolar nerve canal and the apexes of the mandibular first and second molars on panoramic and CBCT images was measured and compared in this study.

Methods. One hundred mandibular first and second molars (with bilateral mesial and distal roots) were selected in 44 patients for this cross-sectional descriptive examination of patient records from the Tabriz School of Dentistry's archives, on panoramic and CBCT images taken simultaneously. In both images, the distances of the apexes of the lower 1st and 2nd molars from the inferior alveolar nerve canal were measured. The images were reviewed by an observer (a maxillofacial radiologist). The data was analyzed by SPSS 20 using the t-test.

Results. CBCT and panoramic images of 100 teeth (38% first molar and 62% second molar) of both mesial and distal roots on the right and left sides of 44 patients were examined. On CBCT and panoramic pictures, there were no discernible variations between the mesial and distal mandibular first and second molar apexes on the left and right sides from the inferior alveolar canal.

Conclusion. There was no significant difference between CBCT and panoramic images in delineating the distance between the lower 1st and 2nd molars' apexes and the inferior alveolar nerve canal.

Keywords: CBCT and panoramic views, first molar, inferior alveolar nerve canal, second molar.

**Farrokh Farhadi¹,
Zeinab Torab², Ladan
Hefzollesan³, Seddigheh
Razi⁴, Majid
Abdolrahimi⁵,
Hamidreza Mohammadi^{6*}**

¹Department of Oral and Maxillofacial Surgery, Faculty of Dentistry, Tabriz University of Medical Sciences, Tabriz, Iran

²Assistant Professor, Department of pediatric dentistry, Tabriz university of medical sciences,

z.torab.pajuhan@gmail.com

³DDS, Private Practice, Tabriz

⁴Department of Oral and Maxillofacial Radiology, Faculty of Dentistry, Tabriz University of Medical Sciences, Tabriz, Iran

⁵Department of Endodontics,

Faculty of Dentistry, Tabriz University of Medical Sciences, Tabriz, Iran

⁶Department of Periodontology, Faculty of Dentistry, Tabriz University of Medical Sciences, Tabriz, Iran

*Corresponding Author; Email: h.moh.perio@gmail.com

Introduction

Understanding the inferior alveolar nerve canal's physical position and how it relates to other anatomical markers lowers the possibility of unintentional nerve damage.¹

The inferior alveolar nerve canal passes through the mandible in an anteroposterior direction, but its buccolingual and vertical positions vary from patient to patient.² Understanding the mandibular canal's anatomical position is crucial because of its vulnerability to damage during mandibular procedures.¹ Therefore, the anatomical position of the mandibular canal should always be evaluated to avoid damage to this anatomical structure during invasive surgeries of the mandible, such as osteotomy of the mandible, fracture repair, placement of screws in the bone, orthokinetic surgery, third molar tooth extraction, and dental implant placement.³⁻⁵

Even with today's sophisticated technology, the inferior alveolar nerve canal's proximity to root tissues remains a significant anatomical concern for dental implant surgery and procedures on mandibular molars. In addition, it has been reported that dentoalveolar and apical surgeries can cause

persistent neurological disorders such as paresthesia, dysesthesia, or inferior alveolar nerve anesthesia.^{7,8}

In endodontic applications, various treatment modalities can harm the inferior alveolar nerve, including periapical surgeries, root canal over-instrumentation, root canal irrigation solutions, and over-filing with root canal instruments. If the inferior alveolar nerve (IAN) canal damage occurs due to the endodontic treatment of mandibular second molars, then the first molar and premolars of the mandible are at high risk.^{9,10}

Previous studies have focused on the buccolingual pathway of the inferior alveolar nerve using cadavers, panoramic radiographs, and CBCT. Panoramic radiographs show an image of the entire anatomy of the area, with a lower radiation dose and cost for the patient compared to other x-ray techniques.¹¹ Studies have shown that panoramic radiographs have seven specific signs that determine the potential for the impacted third molar roots to interfere with the inferior alveolar nerve canal. These signs are root fading, root curvature, thinning of the lower canal, the apex of the two branches of the root, narrowing of the mandibular canal, tilting of the mandibular canal, and interference with the canal linea

alba.^{12,13} Nevertheless, the existence or lack of these radiographic signs does not always suggest that the IAN may have been injured.¹⁴

When the panoramic radiographic image shows a relationship between the root of the wisdom tooth with the IAN canal, the use of CBCT is recommended to further investigate and obtain a three-dimensional spatial relationship between these two structures. Notably, CBCT technique has a significantly higher radiation dose compared to panoramic radiography.^{15,16} CBCT has resulted in significant advances in dental imaging and is an excellent diagnostic tool for detecting this canal and making precise measurements of it. In addition, CBCT enables the reconstruction of surrounding anatomical structures.¹⁷

Ishak et al. (2014) looked at the relationship between the roots of the impacted lower third molars and the mandibular canal. They also looked for symptoms on panoramic radiographs, which showed a close relationship between the mandibular canal and the roots of the mandibular latent third molars. They came to the conclusion that it had an inaccurate prediction value. Additionally, the patient has to be referred for CBCT

assessments if the panoramic view shows that the root image overlaps the mandibular canal.¹⁸

This study assessed and compared the distances between the apexes of the lower 1st and 2nd molars from the inferior alveolar nerve canal on panoramic and cone-beam computed tomography (CBCT) images taken concurrently because there had been disputes in the usage of images in prior studies.

Materials and Methods

In this cross-sectional descriptive study, 100 lower 1st and 2nd molars on the right and left sides of the oral cavity in 44 patients (taking $\alpha = 0.05$, power of 80%, difference of 20% in the frequency of cases) were chosen from patient records that Tabriz University of Medical Sciences Faculty of Dentistry received. Correct diagnosis on panoramic and CBCT images prepared simultaneously was evaluated based on a study by Hasani et al.¹⁹ Patients ranged in age from 20 to 60 years and had a closed apex in the first and second molars of the mandible. The samples were excluded from the study in the case of the canal and root superimposition, technical errors in preparing panoramic radiographs, and severe metallic artifacts.

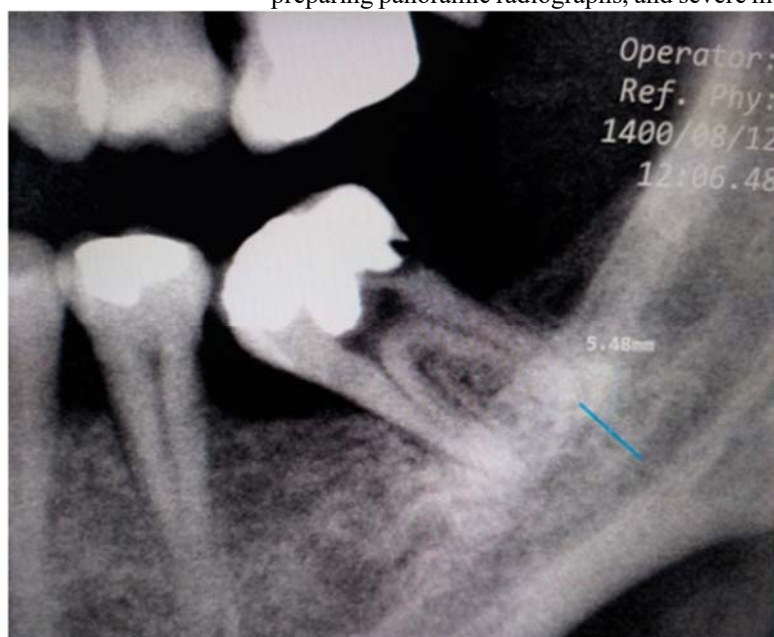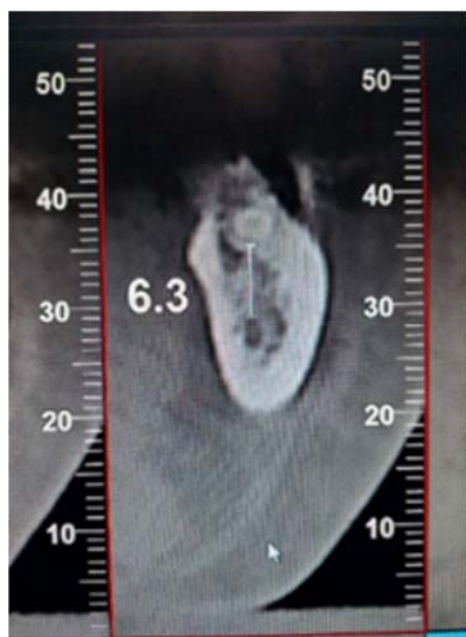


Figure 1

Figure 2

Figures 1 and 2. The radiographic distances between the distal root apex of a mandibular second molar and the inferior alveolar nerve canal on CBCT and panoramic views (left and right, respectively).

Panoramic images were done by Dental X-ray System (model P-Ray Scan α , South Korea) according to the manufacturer's instructions at 90–60 kVp, 60/50 Hz, and 4–17 mA. Scanner 2.0.1 software was used to check these images. Medal Electronic Viewer software was used to fix the inherent magnification of the device and use the measuring tool. CBCT images were taken by the NewTom unit (VGi CT Verona, Italy) in cross-sectional views measuring 1 mm in thickness in the Department of Maxillofacial Radiology, Faculty of

Dentistry, Tabriz University of Medical Sciences. The device has a conical x-ray beam, a flat panel detector with 1536×1920 pixels, 360-degree rotation, 18-second scan time, and a maximum of 110 kVp. NNT viewer 8.0.0 software was used to examine CBCT images. Cases with severe metallic artifacts were excluded. In both image types, the distance between the most distal apex of the mandibular third molar and the inferior alveolar nerve canal was measured.¹⁹ The images were examined by two observers (a maxillofacial radiologist and a

trained senior dental student). The data were registered in a checklist.

Results

This study analyzed CBCT and panoramic images of 100 teeth in 44 patients on both sides of the oral cavity. Since the

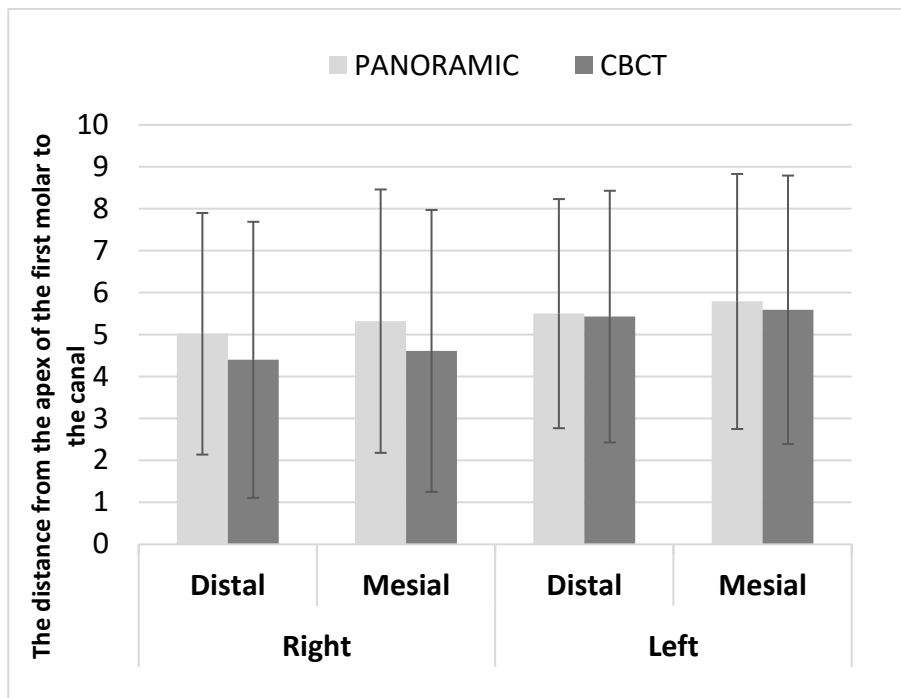
investigated variables (including the distance between the mesial and distal lower 1st and 2nd molar apices and the IAN canal on both the right and left sides) had normal distribution, parametric tests were used to compare the two types of images.

Table 1. Comparison of the radiographic distance between mandibular first and second molars’ apices from the inferior alveolar nerve canal on CBCT and panoramic images on both the right and left sides

			Panoramic		CBCT		P-value
			Mean	SD	Mean	SD	
First molar	Right	Distal	5.02	2.88	4.40	3.29	0.586
		Mesial	5.32	3.14	4.61	3.36	0.552
	Left	Distal	5.50	2.73	5.43	3.00	0.939
		Mesial	5.79	3.04	5.59	3.20	0.828
Second molar	Right	Distal	4.13	2.58	3.62	2.34	0.3
		Mesial	4.48	2.77	3.92	2.28	0.373
	Left	Distal	3.54	2.40	3.34	2.44	0.760
		Mesial	4.28	2.46	4.03	2.55	0.710

Table 1 shows no significant difference in the space between the distal and mesial apices of the right lower first molar and the inferior alveolar nerve canal between CBCT and panoramic images. Also, there was no significant difference between CBCT and panoramic images in both distal and mesial regions on the left side.

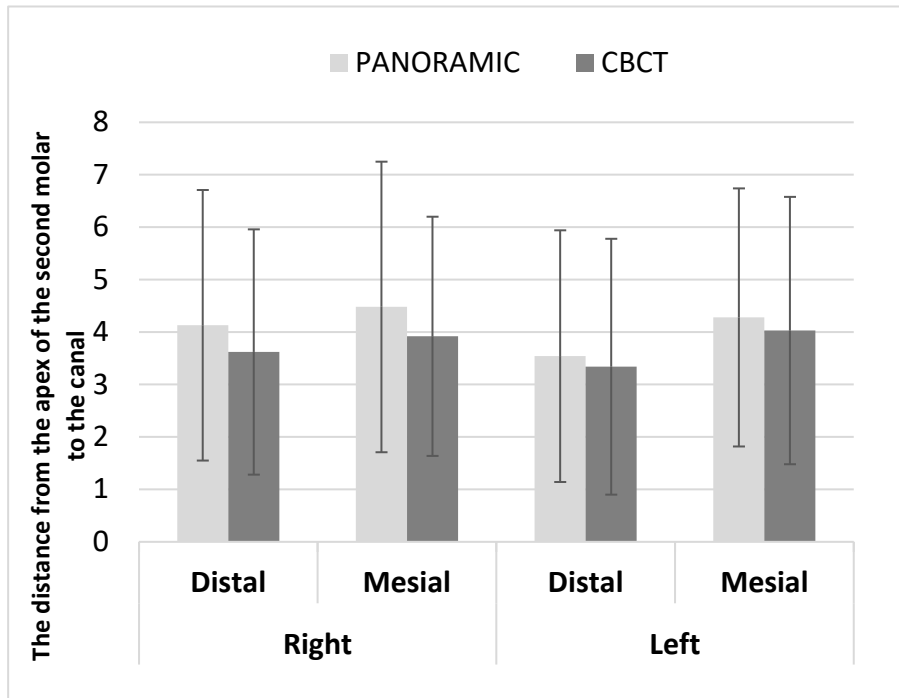
Moreover, no considerable difference exist between the distances of the distal and mesial apices of the right lower second molar from the inferior alveolar nerve canal. Also, there was no significant difference between CBCT and panoramic images in both distal and mesial regions on the left side.



Graph 1. Comparison of the radiographic distance between mandibular first molars' apexes from the inferior alveolar nerve canal on both the right and left sides on CBCT and panoramic images.

Graph 1 shows no significant difference in the radiographic distance among lower first molars' apexes from the IAN canal

on the left and right sides between the CBCT and panoramic views.



Graph 2. Comparison of the radiographic distance between lower 2nd molars' apexes and the inferior alveolar nerve canal on both the right and left sides on CBCT and panoramic images.

Graph 2 shows no significant difference in the distance between lower first molars' apexes and the inferior alveolar nerve canal on the left and right sides on CBCT and panoramic views.

Discussion

This study showed no significant differences between CBCT and panoramic images in the radiographic distances amongst lower first and second molars' apexes from the IAN canal in all the distal and mesial regions on the right and left sides.

Nasser et al²¹ (2018) reported that the panoramic radiographic landmarks were statistically consistent with CBCT landmarks. In addition, Jung et al²² (2012) suggested that panoramic radiographic landmarks were statistically associated with CBCT findings (P<0.01) in a study of 175 teeth.

Moshfeghi et al²³ (2013) further stated that the most dependable and widely available imaging method is panoramic radiography, which may be employed with confidence. With respect to the study's negative predictive value, panoramic radiography has a 97.3% accuracy rate in determining whether third molar roots are involved with the IAN canal.

According to the location of the canal in association to the tooth (buccal or lingual or mid-root-upper or lower), as well as

the type of connection, Mohammadpour et al. (2021) investigated cases where a connection of the roots of CBCT suspected the inferior alveolar nerve canal in the mandibular third molars on panoramic radiography. In the event when a radiolucent band or an abrupt alteration in the canal path is seen on the mandibular molar roots, the findings indicated a statistically significant correlation between the panoramic diagnosis and CBC.

A study by Nunes et al²⁵ (2021) showed that four panoramic radiographic signs, Panoramic radiographs showing darkening, deflection, root narrowing, and mandibular canal interruption suggest that CBCT should be carried out while organizing the extraction of impacted mandibular third molars. Beshtawi et al. (2017) assessed the mental foramen's distances in digital panoramic radiographs (DP) and CBCT reformatted panoramic views (CRP). The findings demonstrated that while there were variations in horizontal and vertical linear measurements between the digital and CBCT reformatted panoramic images, the mean variances might be clinically appropriate.

A study by Nayak²⁷ (2017) demonstrated that indications of a strong connection to the mandibular canal on a panoramic radiograph are associated with a true relationship to the canal.

Therefore, the above-mentioned studies are consistent with the present study.

Using panoramic and CBCT images, Nourbakhsh et al. (2021) examined the anatomical placement of the lower 3rd molar root regarding the nerve canal of the inferior alveolar. They asserted that CBCT radiography provides more information than merely a panoramic image on the relationship between the mandibular third molar teeth and the inferior alveolar nerve canal.

Unlike the present study, Ishak et al¹⁸ (2014) evaluated the distance from the apexes of the first and 2nd molars to the inferior alveolar nerve canal on both image types. They came to the conclusion that the tight contact between the roots of the mandibular third molars and the mandibular canal could not be reliably predicted by the presence or absence of radiographic symptoms on panoramic radiography. Thus, if panoramic views show that the mandibular canal and the root overlap, the patient needs to have a CBCT evaluation.

Hasani et al¹⁹ (2015) reported that the panoramic method could not be as effective as CBCT in detecting connections between tooth roots and the canal. Patel et al²⁹ (2020) reported the superiority of CBCT over panoramic imaging when examining the association between the roots of lower 3rd molars and the IAN canal.

These four studies are not consistent with the present study. The differences in study results might be due to the fact that the studies mentioned above evaluated the proximity of third molars to the inferior alveolar nerve canal by radiographic signs. However, the current research measured the distance among the molar apexes and the IAN canal. Furthermore, these four studies evaluated the third mandibular molars. However, the present study evaluated the first and second molars since the panoramic images of the first and second molars are more reliable than the third molars due to the availability of the external oblique ridge, the possibility of the third molar superimposition on the inferior alveolar canal, and different positions of third molars (angulations). In addition, the differences in sample size, gender, and race could be the other causes of inconsistency between them.

In the present study, in both image types, distances in distal regions were shorter than in mesial regions, and longer distances were observed on the left than on the right side. According to a study by Adigüzel et al³⁰ (2012), CBCT images showed that the distal root was closer to the nerve canal than the mesial root in both sexes (30).

In the present study, for both types of images, distances in distal regions were shorter than in the mesial regions, which might be attributed to canal morphology, since there is a slope from third molars to premolars. This study also showed that the distances on the left side were longer than the right side.

Conclusion

No significant differences were seen among CBCT and panoramic images in finding the distances between the lower 1st and 2nd molars' apexes and the IAN canal.

Authors' Contributions

FF contributed to the study concept and design. LH contributed to the study concept and design, collected data, and contributed to the original draft. SR performed radiographic evaluations and measurements. MA contributed to the study concept and design revised the original draft. All the authors read and approved the final manuscript.

Ethics Approval

This study was approved by the Ethics Committee of Tabriz University of Medical Science under the code IR.TBZMED.REC.1400.1077.

Acknowledgments

The authors acknowledge the support by the Faculty of Dentistry, Tabriz University of Medical Sciences.

Funding

The study was self-funded.

Competing Interests

The authors declare that they have no conflicts of interest related to this study.

References

1. Kilic C, Kamburoğlu K, Ozen T, Balcioglu HA, Kurt B, Kutoglu T, Ozan H. The position of the mandibular canal and histologic feature of the inferior alveolar nerve. *Clin Anat.* 2010 Jan;23(1):34-42.
2. Shah NP, Murtadha L, Brown J. Bifurcation of the inferior dental nerve canal: an anatomical study. *Br J Oral Maxillofac Surg.* 2018 May;56(4):267-271.
3. Puciło M, Lipski M, Sroczyk-Jaszczyńska M, Puciło A, Nowicka A. The anatomical, relationship between the roots of erupted permanent teeth and the mandibular canal: a systematic review, *Surg Radiol Anat.* 2020 May;42(5):529-542.
4. Ghaeminia H., Perry J., Nienhuijs M. E., Toedtling V., Tummers M., Hoppoeneijs T. J., Van der Sanden W. J., Mettes T. G. Surgical removal versus retention for the management of asymptomatic disease-free impacted wisdom teeth. *Cochrane Database Syst Rev.* 2016;(8): CD003879.3.
5. Siddiqui S. R., Agrawal S., Monga H. S., Gaur A. Prophylactic removal of the third molars: Justified or not. *J Int Oral Health.* 2015;7(11): 132-5.

6. Del Lhano NC, Ribeiro RA, Martins CC, Assis NMSP, Devito KL. [Panoramic versus CBCT used to reduce inferior alveolar nerve paresthesia after third molar extractions: a systematic review and meta-analysis.](#) *Dentomaxillofac Radiol*. 2020 May 1;49(4):20190265.
7. Reia VCB, de Toledo Telles-Araujo G, Peralta-Mamani M, Biancardi MR, Rubira CMF, Rubira-Bullen IRF. [Diagnostic accuracy of CBCT compared to panoramic radiography in predicting IAN exposure: a systematic review and meta-analysis.](#) *Clin Oral Investig*. 2021 Aug;25(8):4721-4733.
8. Derafshi A, Sarikhani K, Mirhosseini F, Baghestani M, Noorbala R, Kaboodsaz Yazdi M. Evaluation of the Course of Inferior Alveolar Canal and its Relation to Anatomical Factors on Digital Panoramic Radiographs. *J Dent (Shiraz)*. 2021 Sep;22(3):213-218.
9. Castro R, Guivarc'h M, Foletti JM, Catherine JH, Chossegras C, Guyot L., Endodontic-related inferior alveolar nerve injuries: A review and a therapeutic flow chart. *J Stomatol Oral Maxillofac Surg*. 2018 Nov;119(5):412-418.
10. Lampert RC, Nesbitt TR, Chuang SK, Ziccardi VB. , Management of endodontic injuries to the inferior alveolar nerve., *Quintessence Int*. 2016;47(7):581-7 .
11. Mehdizadeh M, Ahmadi N, Jamshidi M. Evaluation of the relationship between mandibular third molar and mandibular canal by different algorithms of cone - beam computed tomography. *J Contemp Dent Pract* 2014;15(6): 740-5.
12. Hekmatian E, Haghghat A, Alavi S. Evaluation of the ability of panoramic radiography to show the real relationship between embedded wisdom teeth and inferior alveolar canal by visiting a surgical technique. *J Isfahan Dent Sch* 2012;8(7): 669-75. [In Persian]
13. Blaeser BF, August MA, Donoff RB, Kaban LB, Dodson TB. Panoramic radiography risk factors for inferior alveolar nerve injury after third molar extraction. *J Oral Maxillofac Surg* 2003;61(4): 417-21.
14. Neves FS, Souza TC, Almeida SM, Haiter- Neto F, Freitas DQ, Bóscolo FN. Correlation of panoramic radiography and cone beam CT findings in the assessment of the relationship between impacted mandibular third molars and the mandibular canal. *Dentomaxillofac Radiol* 2012;41(7): 553-7.
15. Mahasantipiya PM, Savage NW, Monsour PA, Wilson RJ. Narrowing of the inferior dental canal in relation to the lower third molar. *Dentomaxillofac Radiol* 2005;34(3):154-63.
16. Obman A, Kivijarvi K, Blomback U, Fly gare L. Preoperative radiographic evaluation of lower third molars with computed tomography. *Dentomaxillofac Radiol* 2006;35(1): 30-5.
17. Dabbaghi A, RazaviM, Shirafkan S, Haghghizadeh MH. Evaluation of Inferior Alveolar Canal position in Cross Sectional Cone Beam Computed Tomography Images. *Jundishapur Sci Med J* 2014;13(4):445-455.
18. Ishak MH, Zhun OC, Shaari R, Rahman SA, Hasan MN, Alam MK. Panoramic radiography in evaluating the relationship of mandibular canal and impacted third molars in comparison with cone - beam computed tomography. *Mymensingh Med J* 2014;23(4): 781-6.
19. Hasani A, Modaresi A, Razzaghi N, Ruhi P, Investigating the radiographic error rate in the diagnosis of the lower wisdom tooth root connection with the inferior alveolar nerve canal, *Journal of Research in Dental Sciences*, Winter 2015, Volume 13, Number 4, 50: 209-201.
20. Del Lhano NC, Ribero RA, Martins CC, Assis NM, Devito KL. Panoramic versus CBCT used to reduce inferior alveolar nerve paresthesia after third molar extractions: a systematic review and meta-analysis. *Dentomaxillofac Radiol*. 2020;49(4):20200265.
21. Nasser A, Altamimi A, Alomar A, AlOtaibi N. Correlation of panoramic radiograph and CBCT findings in assessment of relationship between impacted mandibular third molars and mandibular canal in Saudi population. *Dent Oral Craniofac Res*. 2018;4(4):1-5.
22. Jung Y-H, Nah K-S, Cho B-H. Correlation of panoramic radiographs and cone beam computed tomography in the assessment of a superimposed relationship between the mandibular canal and impacted third molars. *Imaging Sci Dent*. 2012;42(3): 121-7.
23. Moshfeghi M, Ghaznavi A, Mohseni M, Nikneshan S. The Ability of Panoramic Radiography in Determining the Relationship of Mandibular Third Molar Roots with the Inferior Alveolar Canal. *The Journal of Islamic Dental Association of IRAN (JIDA)*. 2013; 25 (3): 206-210.
24. Mohammadpour Z, Foroughi R, Abesi F, Bijani A, Haghanifar S. Radiographic Comparison of the Relation between Mandibular Third Molar Root and Inferior Alveolar Canal in Panoramic Radiography and Cone-Beam Computed Tomography. *J Babol Univ Med Sci*. 2021;23: 289-96.

25. Nunes WJ, Vieira AL, de Abreu Guimaraes LD, de Alcantara CE, Verner FS, de Carvalho MF. Reliability of panoramic radiography in predicting proximity of third molars to the mandibular canal: A comparasion using cone-beam computed tomography. *Imaging Sci Dent.* 2021;51(1): 9-16.
26. Beshtawi KR. The accuracy of the mental foramen position on panoramic radiographs and CBCT.2017.
27. Nayak DS. An evaluation of relationship of impacted mandibular third molars and mandibular canal using panoramic radiography and CBCT. InProceedings of 21st IADMFR/TAOMFR 2017 World Congress, Kaohsiung, Taiwan (p. 163).
28. Nourbakhsh S R, Yosefpour H, Osmani F. Comparision of anatomiacal position of the root of third mandibular incisor relative to the alveolar canal in the two methods of panoramic radiograpy and CBCT. *jdm.* 2021;34: 1-7.
29. Patel PS, Shah JS, Dudhia BB, Butala PB, Jani YV, Macwan RS. Comparison of panoramic radiograph and cone beam computed tomography finding for impacted mandibular third molar root and inferior alveolar nerve canal relation. *Indian J Dent Res.* 2020;31(1):91-102.
30. Adigüzel, Yiğit-özer S, Kaya S, Akkuş Z. Patient-specific factors in the proximity of the inferior alveolar nerve to the tooth apex. *Med Oral Patol Oral Cir Bucal.* 2012 Nov;17(6): 1103-8.