

# Maternal and Fetal Outcomes in Pregnancies Affected by Osteosarcoma of the Jaw: A Case Report

## Abstract

The occurrence of cancers during pregnancy is very rare. The common malignancies during pregnancy include breast and cervical cancers, however, head and neck malignancies, on the other hand, are particularly rare, including osteosarcoma. The occurrence of osteosarcoma of the jaw during pregnancy is extremely rare, and its diagnosis can be challenging. When osteosarcoma is detected in pregnancy, the prognosis of both the mother and the fetus may be compromised. This article describes a case of osteosarcoma of the jaw in a 29-year-old African woman in her 28<sup>th</sup> gestation week. She presented with a complain of a painful facial swelling for nearly 3 months. The swelling was preceded by a toothache in the posterior aspects of the left side of the upper jaw. She underwent a series of surgical procedures but the lesion recurred, and subsequently, chemotherapy was administered to her, however, the disease did not respond well and she subsequently succumbed to her disease. Here we discuss the challenges of diagnosis, management, and outcome of treatment for osteosarcoma of the jaw bone in pregnancy.

**Keywords:** *Osteosarcoma, Maxilla, Pregnancy, Maternal, Fetus*

## Introduction

The occurrence of cancers during pregnancy is very rare.<sup>[1, 2]</sup> While the common gestational malignancies are breast and cervical cancers followed by hematological tumors,<sup>[1, 3]</sup> head and neck malignancies on the other hand, are particularly rare.<sup>[3, 4]</sup> Though the spectrum of head and neck cancer is dominated by squamous cell carcinomas,<sup>[5, 6]</sup> a few cases of osteosarcoma of the jaws in pregnancy have been documented.<sup>[3, 6, 7]</sup> Osteosarcoma commonly affects the long bones of the extremities near the metaphyseal growth plate.<sup>[7, 8]</sup> The involvement of jaws is extremely rare, representing only 1% of all primary tumors arising within the head and neck region and accounting for 4 to 10% of all sarcomas.<sup>[9, 10]</sup>

When head and neck malignancies are detected during pregnancy, the prognosis of the mother and the fetus may be compromised.<sup>[11, 12]</sup> Yet still, there is a lack of proper guidelines for appropriate management of the condition due to the rareness of this co-existence.<sup>[13, 14]</sup> Considering the rarity of such cases, it is crucial to document them when they occur and therefore contribute to the global data

This is an open access journal, and articles are distributed under the terms of the Creative Commons Attribution-NonCommercial-ShareAlike 4.0 License, which allows others to remix, tweak, and build upon the work non-commercially, as long as appropriate credit is given and the new creations are licensed under the identical terms.

For reprints contact: [Support\\_reprints@ccij-online.org](mailto:Support_reprints@ccij-online.org)

© 2023 Clinical Cancer Investigation Journal

pool. Here we report a case of a pregnant woman diagnosed with osteosarcoma of the upper jaw, its management, and the outcome.

## Case reports

A 29-year-old African female patient in the 28<sup>th</sup> gestation week was referred to the Department of Oral and Maxillofacial Surgery in July 2022. She complained of painful facial swelling for nearly 3 months. According to her, the swelling was preceded by a toothache in the posterior aspects of the left side of the upper jaw. After about a week, the painful swelling occurred in the same region and was gradually increasing in size.

She decided to seek medical attention and visited an oral and maxillofacial surgeon whose initial diagnosis was a central giant cell tumor of the maxilla. A tissue biopsy was taken from the tumor, and the lesion was histologically diagnosed as an odontogenic fibroma. Based on the diagnosis, tumor enucleation was carried out. Approximately 8 days after the surgery, the swelling recurred. It was painful and was increasing in size over time. As the tumor

**Arnold A Mtenga<sup>1</sup>,  
Karpal Singh  
Sohal<sup>1,2\*</sup>, Arvinder  
Singh Sohal<sup>3</sup>, Subira  
Bhoke Matiku<sup>4</sup>,  
Joseph N. Mfuse<sup>1</sup>**

<sup>1</sup>Department of Dental Services, Muhimbili National Hospital, Dar es Salaam, Tanzania. <sup>2</sup>Department of Oral and Maxillofacial Surgery, Muhimbili University of Health and Allied Sciences, Dar es Salaam, Tanzania. <sup>3</sup>Department of Obstetrics and Gynecology, Regency Medical Centre, Dar es Salaam, Tanzania. <sup>4</sup>Department of Anatomical Pathology, Muhimbili University of Health and Allied Sciences, Dar es Salaam, Tanzania.

## Address for correspondence:

Karpal Singh Sohal,  
Department of Dental Services,  
Muhimbili National Hospital, Dar  
es Salaam, Tanzania.  
E-mail: [karpal@live.com](mailto:karpal@live.com)

## Access this article online

Website: [www.cci-j-online.org](http://www.cci-j-online.org)

DOI: [10.51847/5mbQ9uGX8I](https://doi.org/10.51847/5mbQ9uGX8I)

## Quick Response Code:



**How to cite this article:** Mtenga AA, Sohal KS, Sohal AS, Matiku SB, Mfuse JN. Maternal and Fetal Outcomes in Pregnancies Affected by Osteosarcoma of the Jaw: A Case Report. *Clin Cancer Investig J.* 2023;12(4):14-8.  
<https://doi.org/10.51847/5mbQ9uGX8I>

progressed, it led to nasal obstruction, loosening of teeth, and chewing difficulties. The patient was therefore referred to us for further management.

On physical examination, the patient had a huge swelling on the left side of the face that extended from the superior orbital rim to the level of the lower jaw. The overlying skin was slightly reddish, displacing the left eye upwards and the nose to the right. On palpation, it was warm, firm to hard, fixed to underlying tissues, and tender (**Figure 1a**). Intraorally, the lesion occupied the entire left side of the upper jaw extending just a few millimeters to the midline of the palate. The lesion was lobulated, with a keratotic, granular, and ulcerated overlying mucosa in most areas but smooth in some regions. The color of the mucosa covering the lesion was reddish-purple.

The workup done on the patient included histopathological analysis, a CT scan of the craniofacial region, a conventional radiograph of the chest, a complete blood count, serum electrolytes, and liver and renal function test. The CT scan images revealed a huge heterogenous mass in the left upper alveolar ridge extending to the buccal and masticatory spaces, nasal cavity, and paranasal sinuses (**Figures 2a-2c**). The chest x-ray and blood test were normal except for the hemoglobin level of 10.1g/dl. The incisional biopsy results revealed the tumor was diagnosed as osteosarcoma (**Figure 3a**).

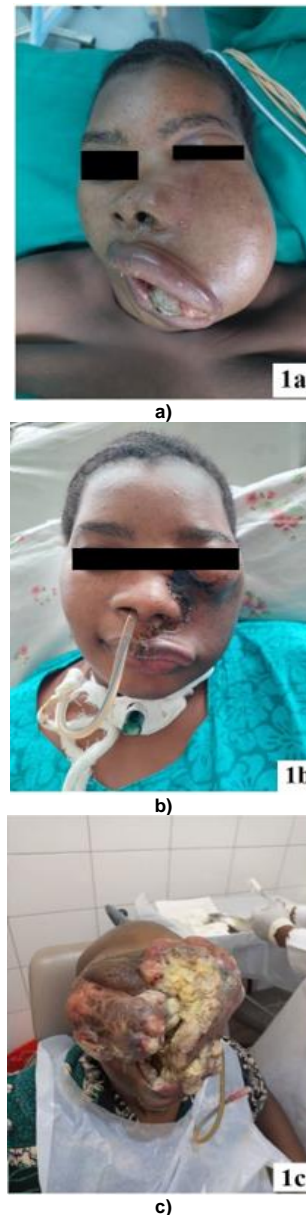She was discussed in a panel of maxillofacial surgeons and planned for surgery followed by adjuvant chemo-radiotherapy. The patient and her relatives were counseled, and treatment options were discussed in depth. A multidisciplinary approach was required, involving the anaesthesiologists, obstetricians & gynecologists (ObGy), pediatricians, and otolaryngologists (ENT surgeons). The ObGy estimated the gestation age of 29 weeks + 5 days, and they planned a cesarian section to deliver the baby on the day of surgery for the tumor. The anaesthesiologists assessed the patient and deemed her fit for general anesthesia. However, due to anticipated difficult intubation, tracheostomy was necessary. After consenting to the surgeries, she underwent tracheostomy, C/section, and wide tumor excision on the same sitting. The surgeries were uneventful. A healthy preterm baby boy was delivered, and the tumor was excised widely.

Immediately after surgery, the patient was admitted to the Intensive Care Unit (ICU) for 5 days, whereas the neonate was admitted to the Neonatal Intensive Care Unit (NICU). The patient spent another 1 week in the ward for post-op care (**Figure 1b**). The post-operative histological results were suggestive of osteosarcoma (**Figure 3b**). On the 3<sup>rd</sup> week postoperatively, her case was discussed in the tumor board meeting and subsequently transferred to a cancer institute for adjuvant chemotherapy.

However, before starting the chemotherapy sessions, the lesion recurred around the region of the left lower eyelid and kept on increasing in size despite the subsequent initiation of

chemotherapy. With time elapsing, the lesion recurred and grew rapidly. It subsequently ulcerated and bled.

After the 3<sup>rd</sup> cycle of chemotherapy, the oncologists referred her back to us for assessment of the possibility of another surgery (**Figure 1c**), because the tumor was not responding to treatment. The panel of maxillofacial surgeons decided the tumor was inoperable, and hence recommended palliative care, and she complete the remaining three cycles of chemotherapy. Palliative care entailed pain management and daily wound care. The patient eventually succumbed to her illness in December 2022. On the other hand, the baby boy has grown strong and healthy as he celebrates his 1<sup>st</sup> birthday.



**Figure 1.** Clinical appearance of the patient. (a) a massive tumor involving the left side of the face, displacing the left eye superiorly and the nose to the right. (b) The post-operative appearance of the patient following wide tumor resection. (c) Clinical presentation of the patient after the tumor recurred. The tumor is shown to have ulcerated and caused significant deformity

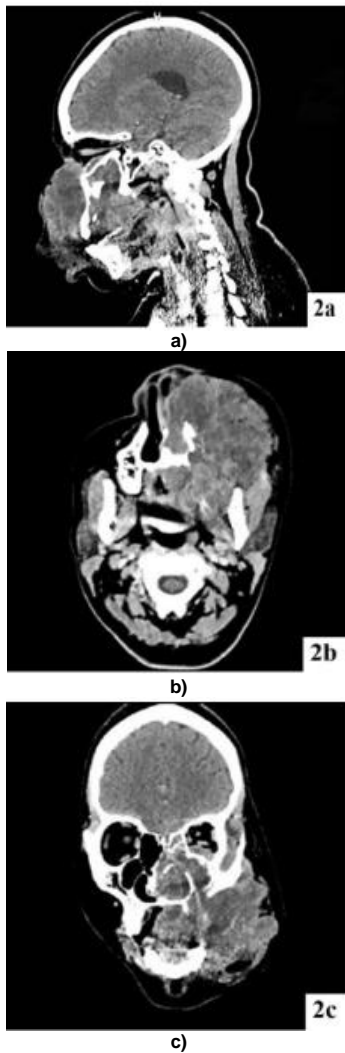


Figure 2. Selected computed tomography (CT) scan of the maxillary lesion (a) sagittal view, (b) axial view, and (c) coronal view. The CT scan demonstrates a heterogeneous soft tissue mass, originating from the left maxilla, involving the left paranasal sinuses and the orbital floor destroying the facial bones.

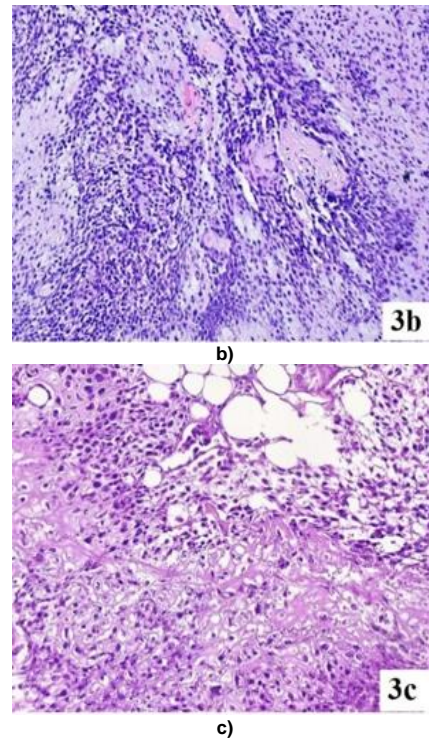
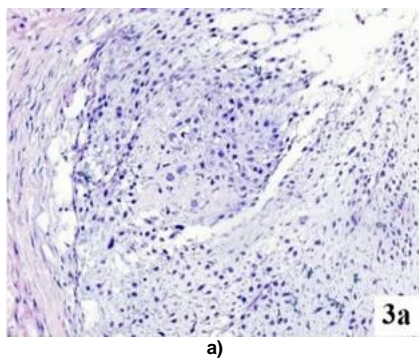


Figure 3. Histopathological images (H&E) of the maxillary lesion: (a) Pre-operative biopsy, showing a poorly circumscribed tumor with pleomorphic spindle cells and irregular osteoid formation (magnification x100). (b) Post-operative, tumor composed of pleomorphic spindled cells with irregular disorganized osteoid formation (magnification x100). (c) A post-operative, tumor composed of pleomorphic spindled cells, large prominent nuclei, disorganized osteoid formation, and abnormal mitoses (magnification x200).

## Results and Discussion

Osteosarcoma of the jaws affects the mandible twice as much as the maxilla.<sup>[7, 15]</sup> The occurrence of osteosarcoma in the jaw during pregnancy is extremely rare, with less than 20 cases reported in English literature.<sup>[16]</sup> To our knowledge, the case we are presenting is one of the rarest in terms of its occurrence in a pregnant female patient and its location in the maxilla.

As noted in the present case, clinical diagnosis of osteosarcoma in pregnancy can be challenging not only due to its uncommonness but also other factors. During the initial phase of the disease, the associated inflammatory signs coupled with limited radiographic assessment in pregnancy render it hard to rule out dental and periodontal infections, thereby misdiagnosing it.<sup>[3]</sup> Moreover, osteosarcoma presents with signs and symptoms that may be common to most maxillary tumors such as swelling, toothache, pain, mucosal ulceration, nasal obstruction, and eye displacement.<sup>[15, 17]</sup> Nearly all these symptoms were present in the case presented herein and hence contributed to clinical misdiagnosis in the initial phase of the disease.

In the present case, it was noted that the rate of recurrence and tumor growth was high. Which might be attributed to the pregnancy state. Some authors hypothesize that pregnancy being a proangiogenic state, coupled with hormonal and immunological changes during pregnancy, are triggers for the



progression of the tumor.<sup>[18]</sup> Dohi *et al.*<sup>[19]</sup> analyzed the presence of estrogen receptor (ER)- $\beta$  and progesterone receptor (PR) in tissue samples of osteosarcoma and found that ER- $\beta$  and PR were positive in the majority of cases. However, Dominguez-Malagón *et al.*<sup>[20]</sup> found negative expression of ER and PR in 95 % and 100% of the 21 cases of jaw-osteosarcoma respectively.

The main therapeutic approach for osteosarcoma is wide surgical resection of the lesion, with some authors advocating the use of adjuvant chemotherapy and radiotherapy as well.<sup>[3]</sup> Considering the lack of proper guidelines for managing osteosarcoma in pregnancy, the panel of oral and maxillofacial surgeons opted for wide tumor excision followed by adjuvant chemo-radiotherapy. The decision of surgery was reached bearing in mind that pregnant women may safely undergo general anesthesia and surgical interventions for non-obstetric indications.<sup>[21]</sup>

Whether or not the pregnancy can reach term depends on the evaluation of the prognosis of the neoplasia and survival.<sup>[18]</sup> Preterm birth via cesarean section can be considered when the patient has to undergo adjuvant chemo-radiotherapy after surgery.<sup>[21]</sup> Iatrogenic preterm birth was thus the major cause of prematurity in the current case. The decision of preterm birth was reached because the diagnosis of osteosarcoma during pregnancy represents a vulnerable time for the mother and fetus, and there is limited data to support the safety of commonly used sarcoma chemotherapy regimens in pregnancy.<sup>[22]</sup> Studies have shown that chemotherapy during the second or third trimester can lead to intrauterine growth retardation, infertility, and pre-term labor.<sup>[6]</sup> On the other hand, radiotherapy during pregnancy can induce lethal effects, growth impairment, mental retardation, malignancy, and hereditary defects.<sup>[6]</sup>

Unlike the reports from elsewhere<sup>[7, 23, 24]</sup> which documented good prognoses in both mother and fetus after managing osteosarcoma of the jaws during pregnancy, In the present case, the sarcoma did not respond to chemotherapy, and subsequently, the patient died 6 months after the diagnosis. However, the decision of delivering the baby preterm paid off positively as the baby is growing into a healthy and strong boy.

## Conclusion

Osteosarcoma of the jaws during pregnancy affects both the mother and fetus. For better management of osteosarcoma during pregnancy, multidisciplinary teamwork which is patient-centered is very crucial. Thorough counseling to the patient and her family is necessary based on challenges posed by diagnosis. The best treatment strategy and pregnancy interruption must be decided after balancing the risks to the mother and fetus.

## Acknowledgments

None.

## Conflict of interest

None.

## Financial support

None.

## Ethics statement

None.

## References

- Zarkavelis G, Petrakis D, Fotopoulos G, Mitrou S, Pavlidis N. Bone, and soft tissue sarcomas during pregnancy: A narrative review of the literature. *J Adv Res.* 2016;7(4):581-7. doi:10.1016/j.jare.2016.01.003
- Sun Y, Chen Q, Liu P, Zhao Y, He Y, Zheng X, et al. Impact of traditional chinese medicine constitution on breast cancer incidence: A case-control and cross-sectional study. *Pharmacophore.* 2021;12(2):46-56.
- Sanatkhani M, Rasekhi J, Dalirsani Z, Ghazi N. Maxillofacial malignancy in pregnancy; Report of two cases. *Iran J Blood Cancer.* 2019;11(4):143-7.
- El Hadad S, Al Rowily E, Aldahlawi A, Alrahimi J, Hassoubah S. The role of P53 and K-Ras in regulating spleen innate mediators in mice with colon cancer. *Pharmacophore.* 2021;12(4):19-27.
- Sahebzadeh M, Khuzani HR, Keyvanara M, Tabesh E. Explaining the factors shaping two different beliefs about cancer in Iran based on causal layer analysis "CLA". *Entomol Appl Sci Lett.* 2021;8(2):42-50.
- Le Guevelou J, Lebars S, Kammerer E, de Gabory L, Vergez S, Janot F, et al. Head and neck cancer during pregnancy. *Head Neck.* 2019;41(10):3719-32. doi:10.1002/hed.25877
- Mirmohammad Sadeghi H, Karimi A, Derakhshan S, Aminshakib P, Parchami K. Conventional osteosarcoma of the mandible: Report of a rare case. *Clin Case Rep.* 2021;9(9):1-5. doi:10.1002/ccr3.4843
- Aloufi BH. Structure-based multi-targeted molecular docking and molecular dynamic simulation analysis to identify potential inhibitors against ovarian cancer. *J Biochem Technol.* 2022;13(2):29-39.
- Abubaker SA, Abdelwadoud ME, Ali MM, Ahmad HA, Khalfalla AM, Elmahi OM, et al. Immunohistochemical expression of oestrogen and epidermal growth factor receptors in endometrial cancerous in Sudanese patients. *J Biochem Technol.* 2021;12(1):58-62.
- Moshy JR, Owibingire SS, Sohal KS. An 8-year pattern of orofacial sarcoma from the national referral hospital in united republic of Tanzania. *Int J Head Neck Surg.* 2016;7(4):207-12.
- Sato K, Shimamoto H, Mochizuki Y, Hirai H, Tomioka H, Shimizu R, et al. Treatment of oral cancers during pregnancy: A case-based discussion. *J Otolaryngol - Head Neck Surg.* 2019;48(1):1-7. doi:10.1186/s40463-019-0331-1
- Fawzy A, Alqelaiti YA, Almatrafi MM, Almatrafi OM, Alqelaiti EA. Common sensitive prognostic markers in breast cancer and their clinical significance: A review article. *Arch Pharm Pract.* 2022;13(1):40-5.
- Aloufi BH, Alshammari AM. Graphical data representation and analytics to link the potential interaction for lung cancer genes. *Int J Pharm Res Allied Sci.* 2022;11(2):62-72.
- Awang ABC, Mutalip SSM, Mohamed R, Nordin M, Siew JSK, Dasiman R. A review of the effects of vitamin e in ovarian cancer. *Int J Pharm Res Allied Sci.* 2022;11(2):81-5.
- Opoko U, Sabr A, Da Silva FN, Raiteb M, Regragui M, Slimani F. A case of very aggressive maxilar osteosarcoma in a young subject. *Adv Oral Maxillofac Surg.* 2021;3:100144. doi:10.1016/j.adoms.2021.100144
- Anbinder DAL, Santos MT, Américo DMá, Lopes DSé, Carvalho DY. Osteosarcoma of the jaws during pregnancy: Case report and review of the literature. *Oral Surg Oral Med Oral Pathol Oral Radiol* 2019;128(1):e43-4. doi:10.1016/j.oooo.2019.02.087
- Prabhakaran K, Karande A, Jerry J, Rishal Y. Osteosarcoma of the posterior maxilla. *J Int Soc Prev Community Dent.* 2016;6(Suppl 2):S171-4. doi:10.4103/2231-0762.189762
- Ibargüengoitia-Ochoa F, Lira-Plascencia J, Gallardo-Gómez F, Mustre-Juárez CR, Ruiz-Beltrán AM, Sepúlveda-Rivera CM. Sarcomas in

- pregnancy: Two cases and literature review. *Ginecol Obstet Mex.* 2021;89(6):497-502. doi:10.24245/gom.v89i6.4851
19. Dohi O, Hatori M, Suzuki T, Ono K, Hosaka M, Akahira JI, et al. Sex steroid receptors expression and hormone-induced cell proliferation in human osteosarcoma. *Cancer Sci.* 2008;99(3):518-23. doi:10.1111/j.1349-7006.2007.00673.x
  20. Domínguez-Malagón HR, González-Conde E, Cano-Valdez AM, Luna-Ortiz K, Mosqueda-Taylor A. Expression of hormonal receptors in osteosarcomas of the jaw bones: Clinico-pathological analysis of 21 cases. *Med Oral Patol Oral Cir Bucal.* 2014;19(1):44-8. doi:10.4317/medoral.18729
  21. Figueiro-Filho EA, Al-Sum H, Parrish J, Wunder JS, Maxwell C. Maternal and fetal outcomes in pregnancies affected by bone and soft tissue tumors. *AJP Rep.* 2018;8(04):e343-8. doi:10.1055/s-0038-1676289
  22. Miller D, Livingston JA, Park Y, Posey K, Godbole S, Skubitz K, et al. Pregnancy outcomes related to the treatment of sarcomas with anthracyclines and/or ifosfamide during pregnancy. *Cancer Med.* 2022;11(18):3471-8. doi:10.1002/cam4.4707
  23. Santos TA, Américo MG, Priante AVM, de Oliveira MF, Anbinder AL. Jaw osteosarcoma and pregnancy: a rare coexistence. *Autops Case Rep.* 2022;12:e2021359. doi:10.4322/acr.2021.359
  24. Figueiró-Filho E, Horgan R, Muhanna N, Parrish J, Irish J, Maxwell C. Obstetrical outcomes of head and neck (Nonthyroid) cancers: A 27-year retrospective series and literature review. *Am J Perinatol Rep.* 2019;09:e15-22. doi:10.1055/s-0039-1677876